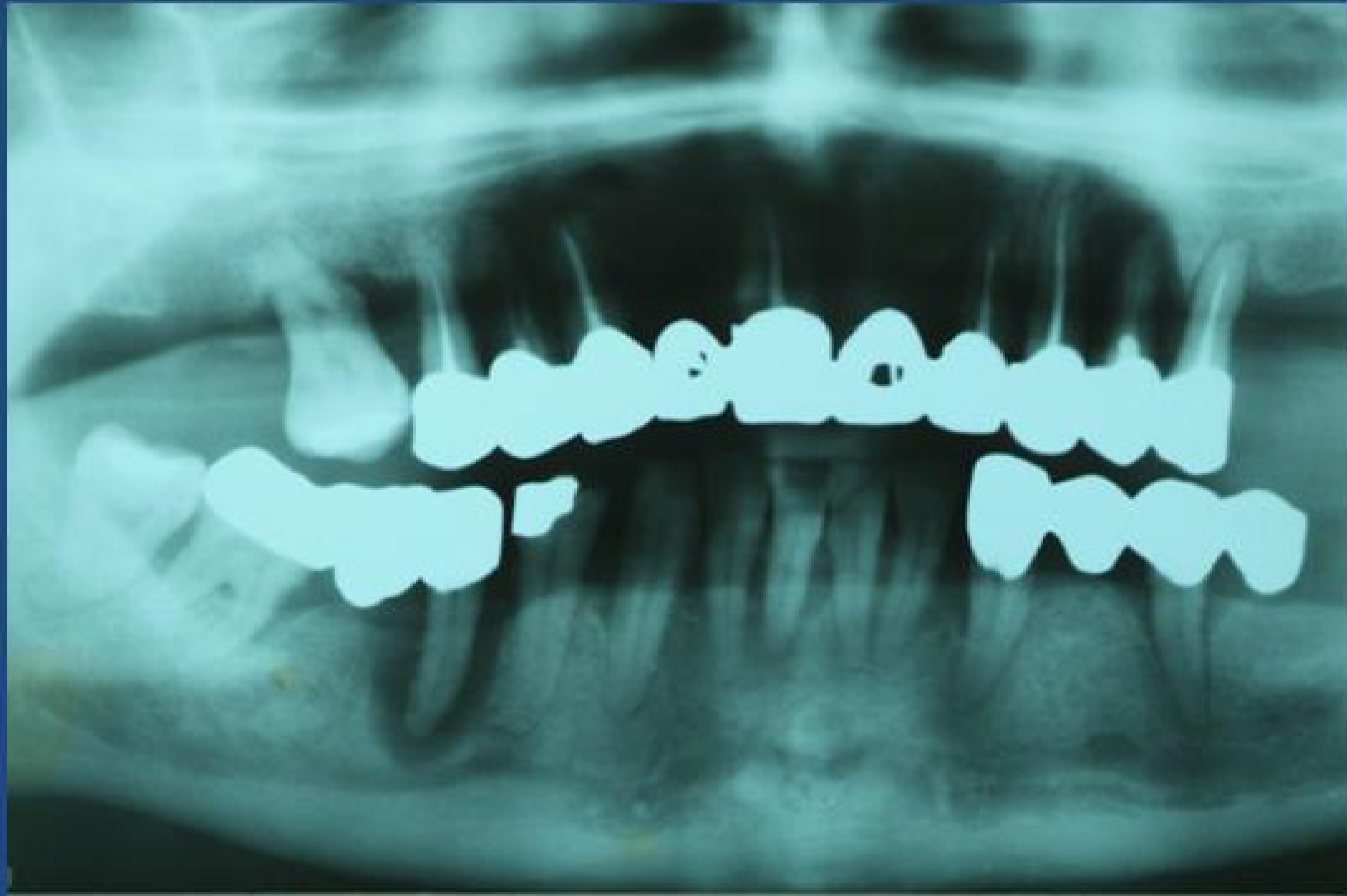
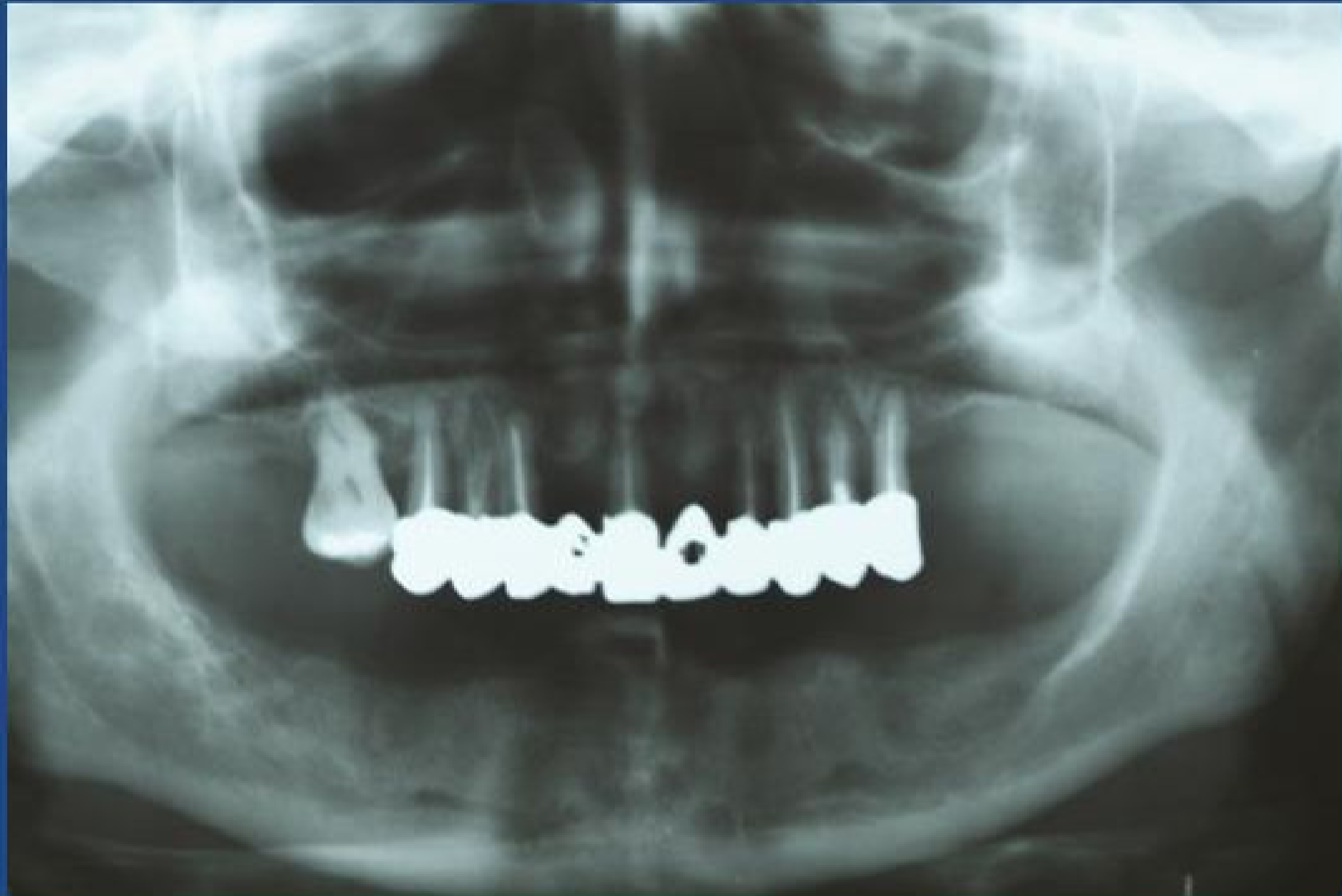
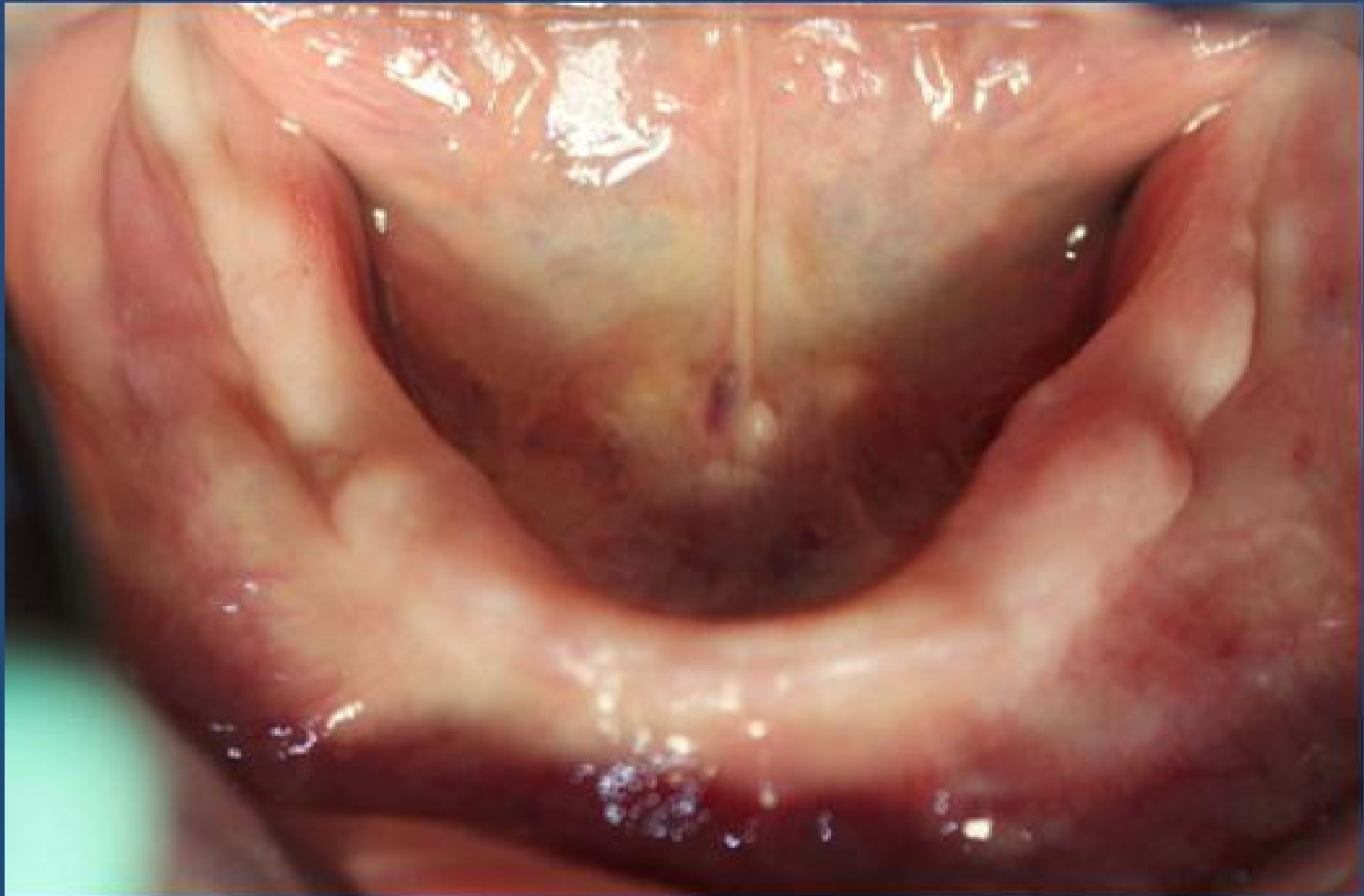Controllo radiografico in prima visita

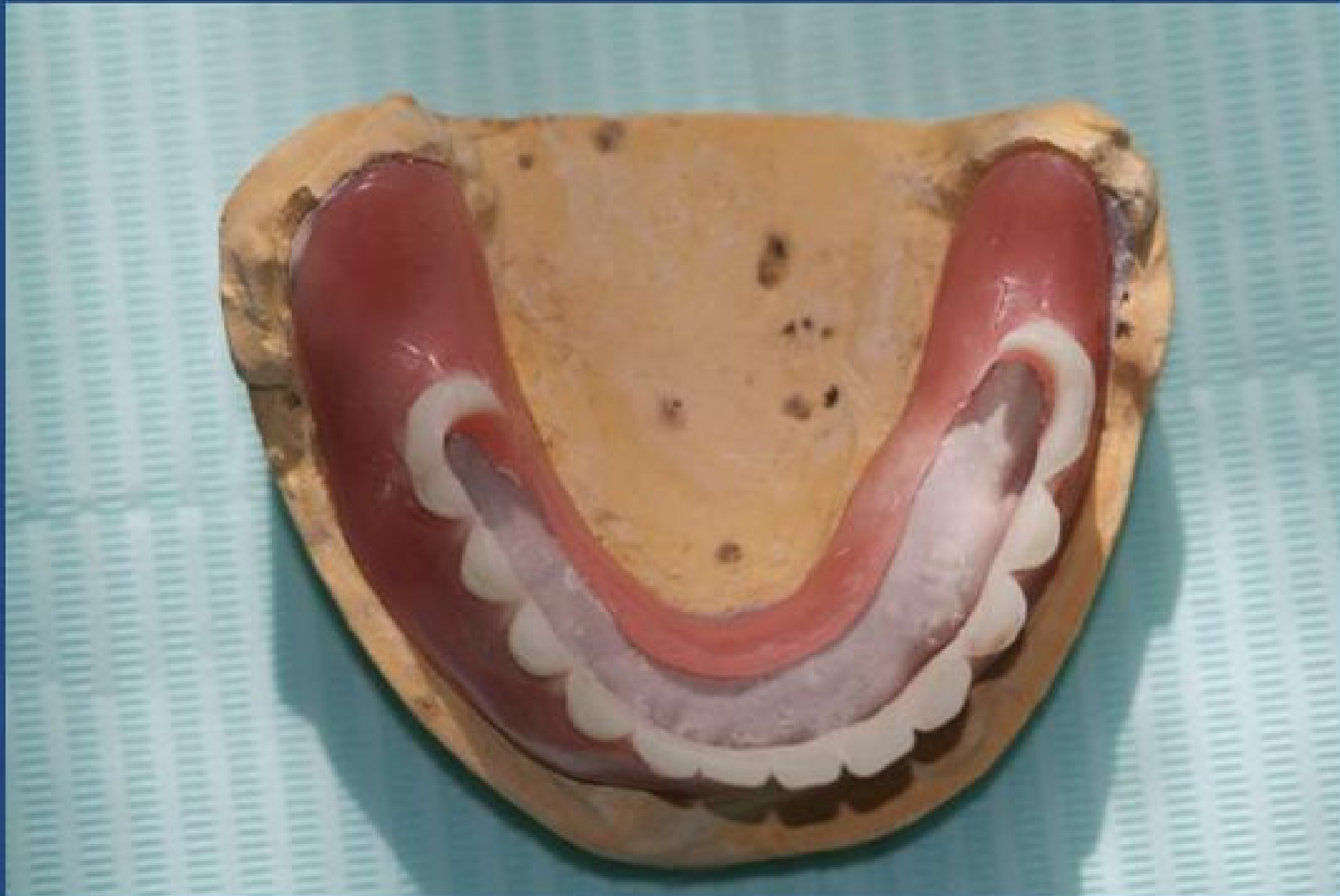

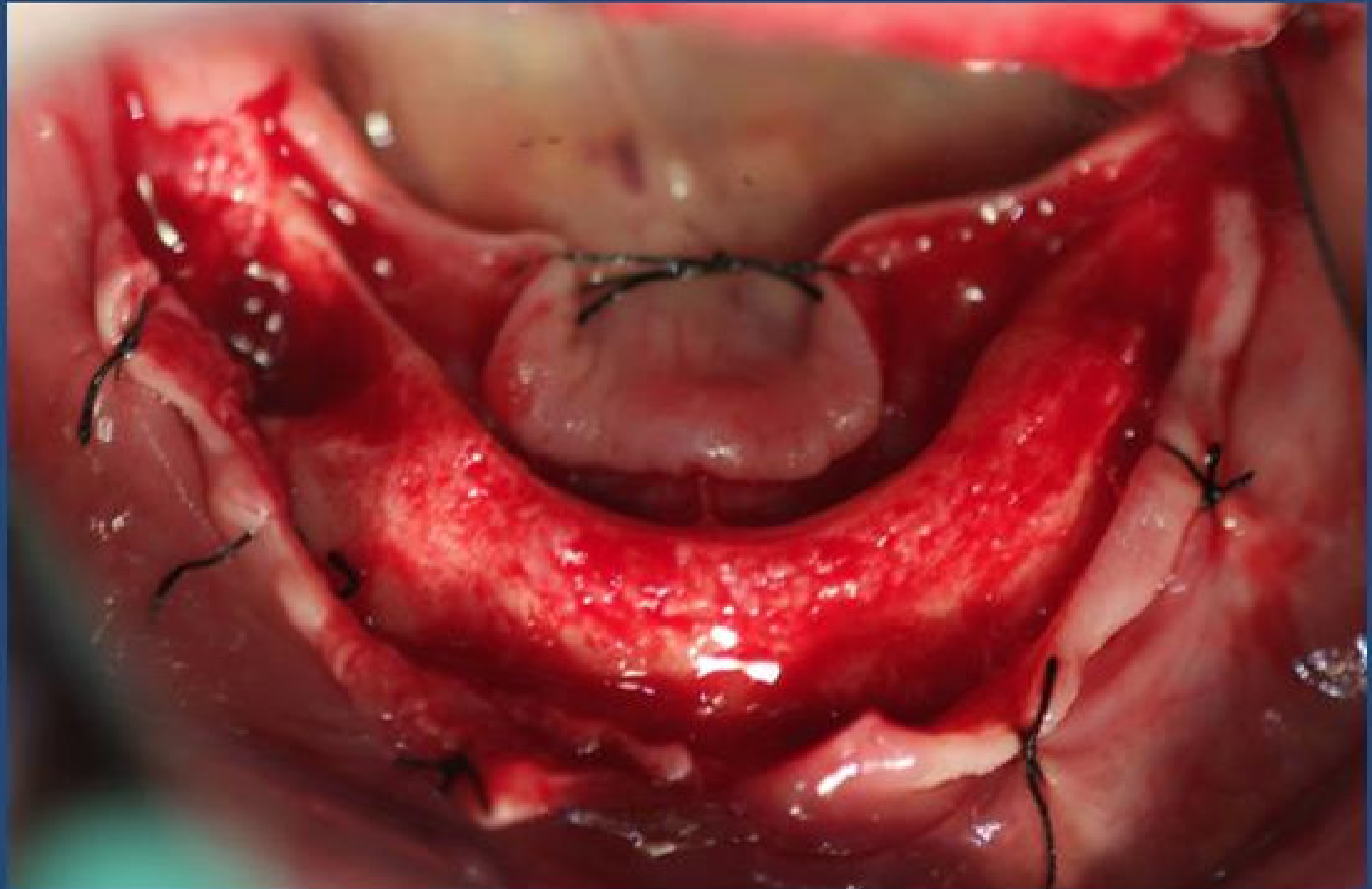
Tre mesi dopo le estrazioni



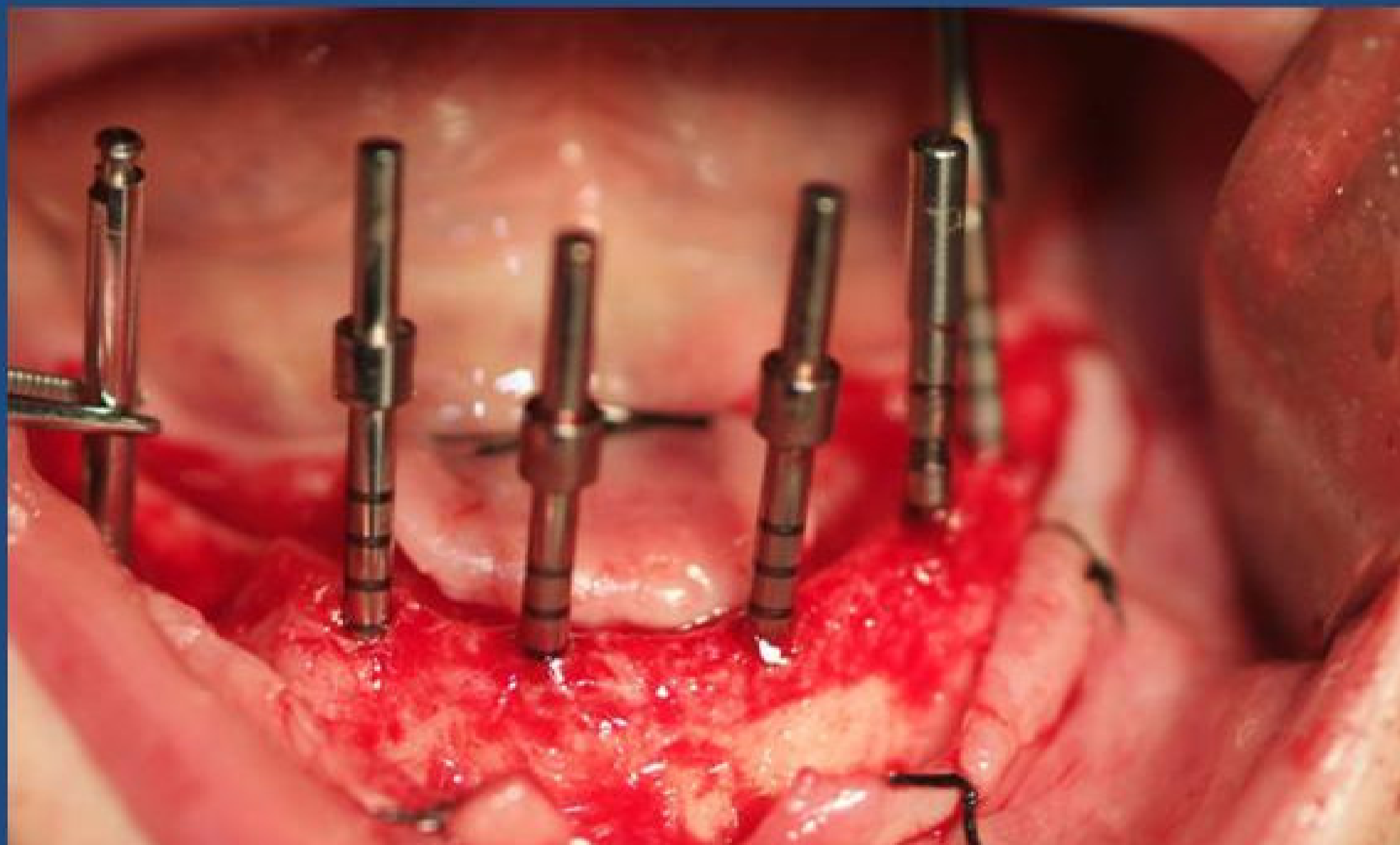


Mascherina chirurgica

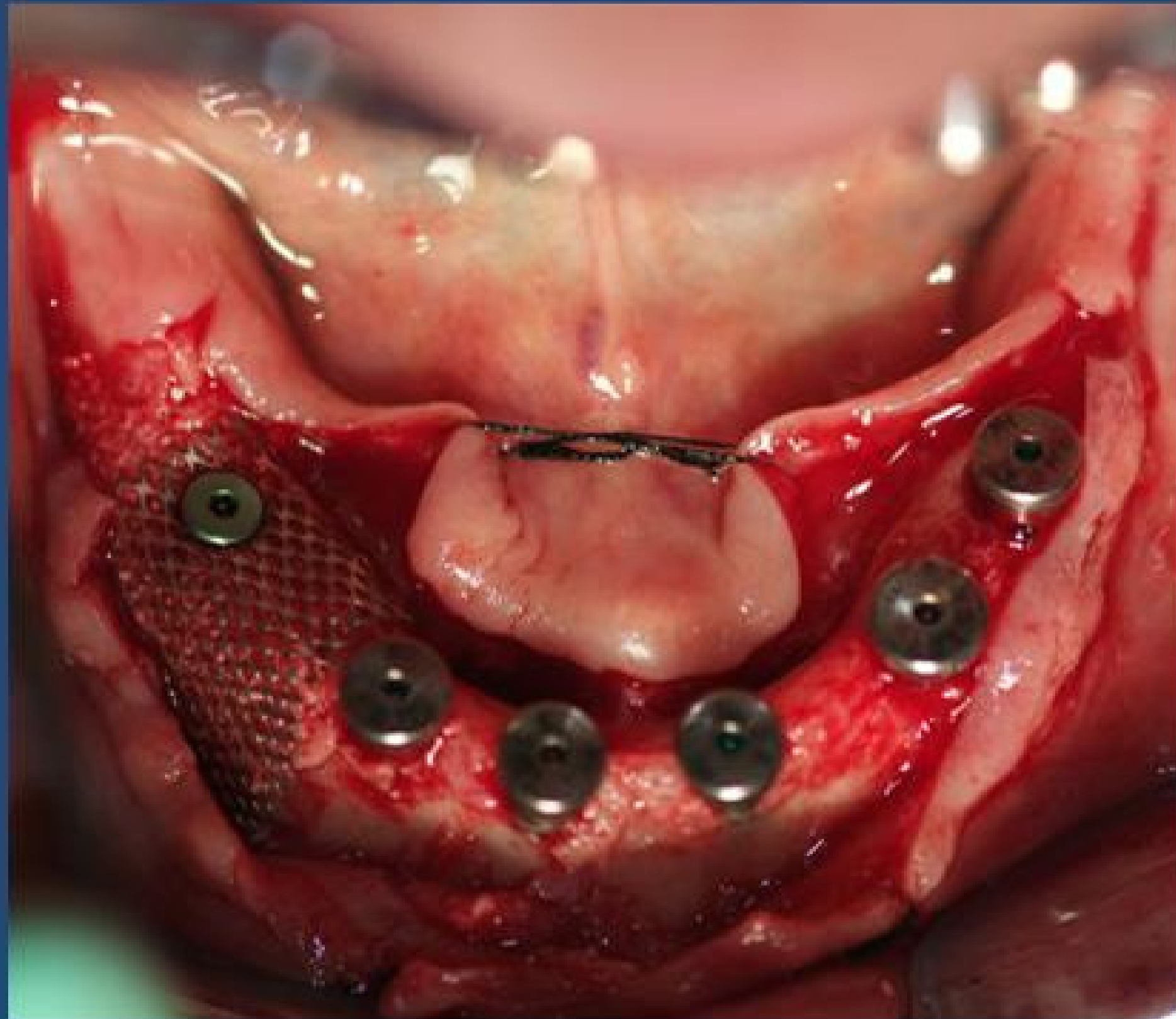


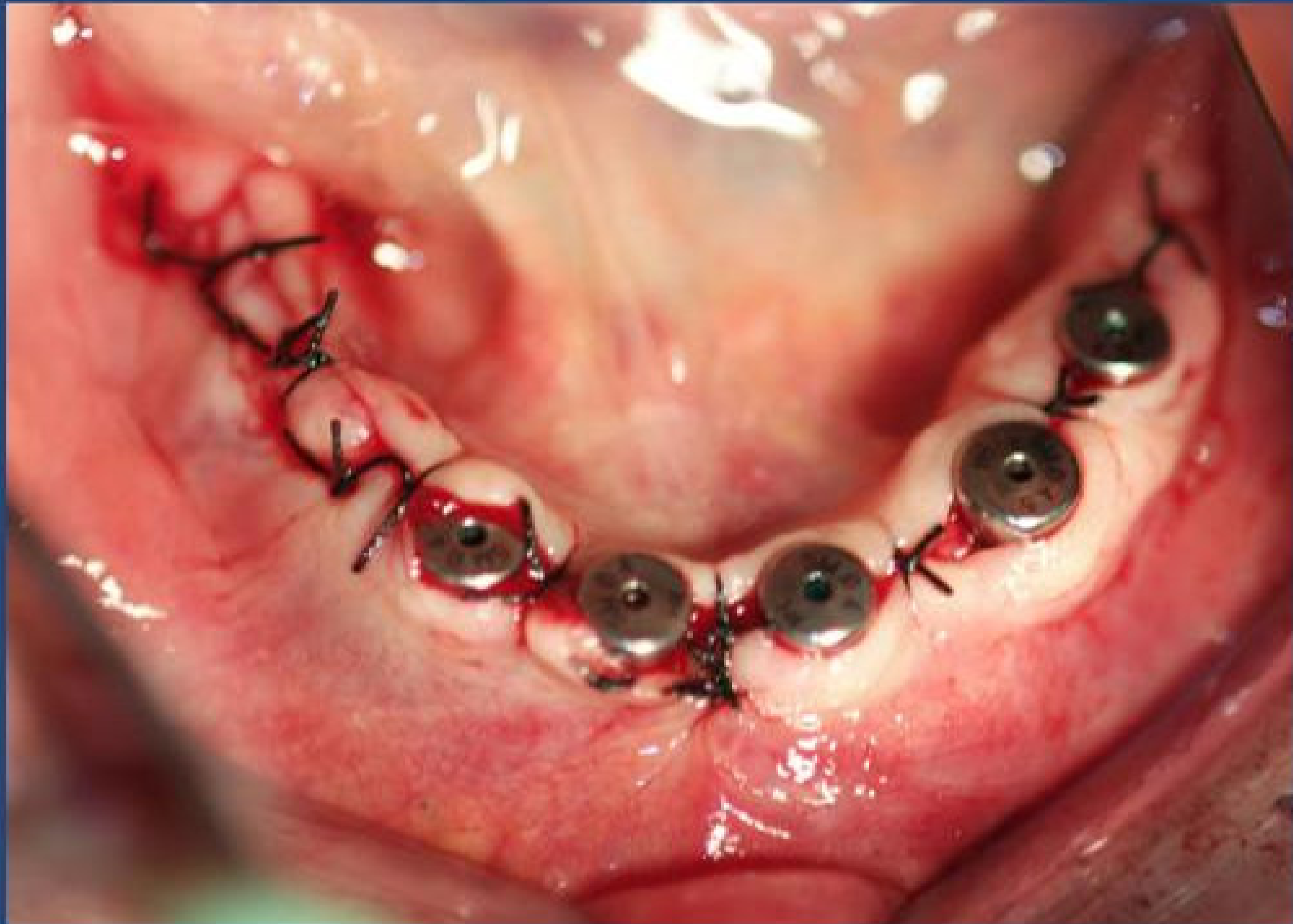

In zona 46 si rigenera con innesto
d'osso particolato e griglia in titanio

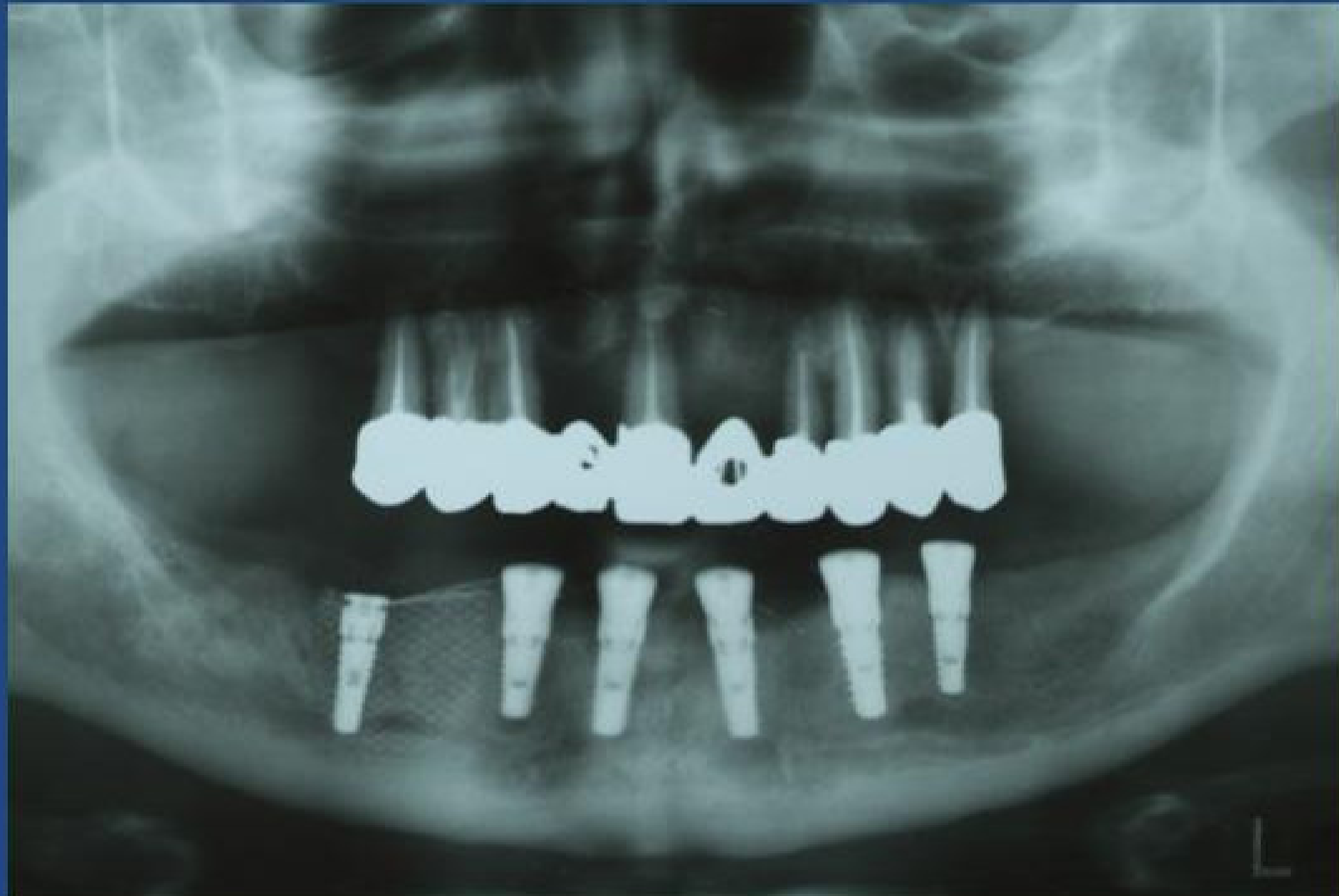


Particolare della griglia fissata .

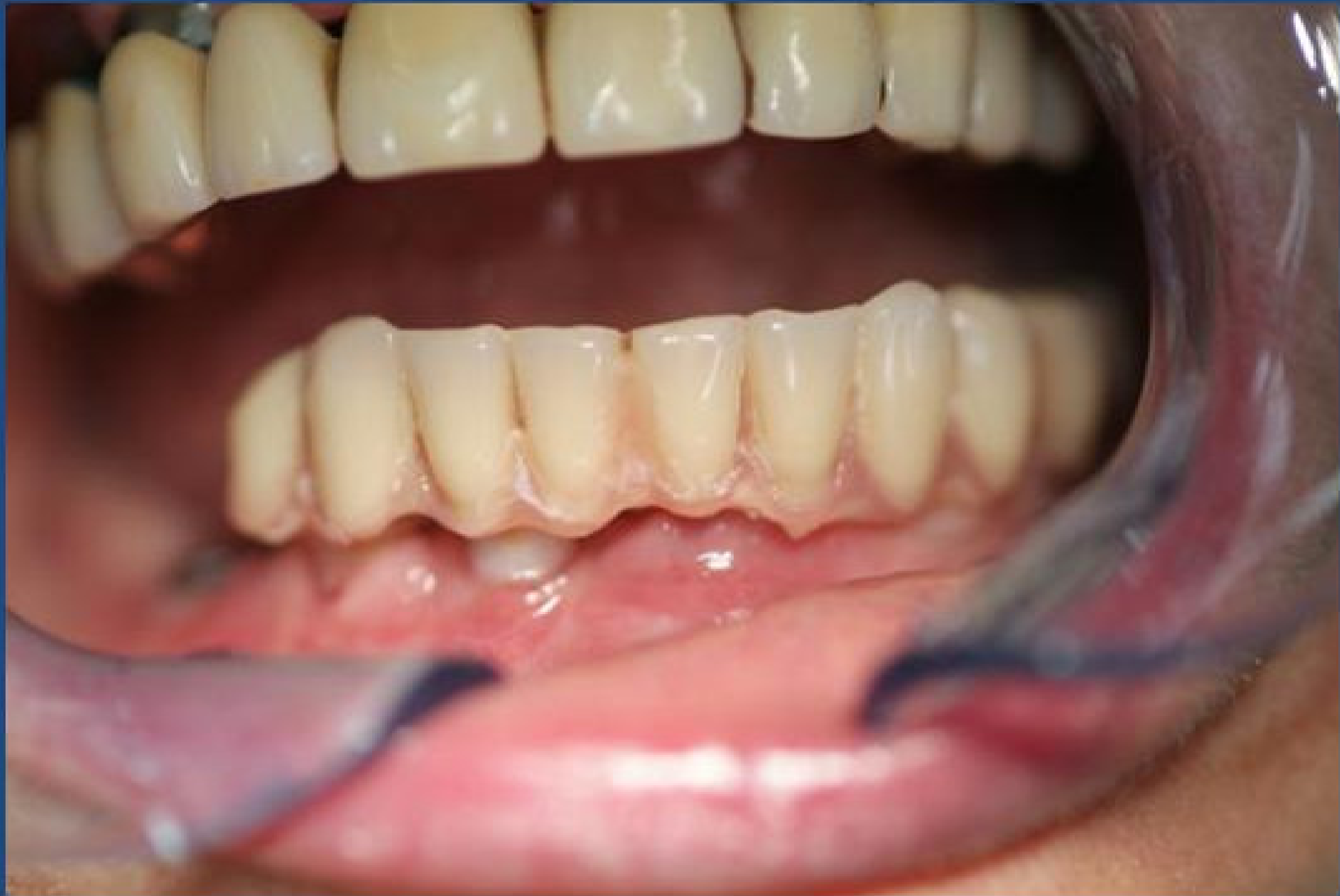



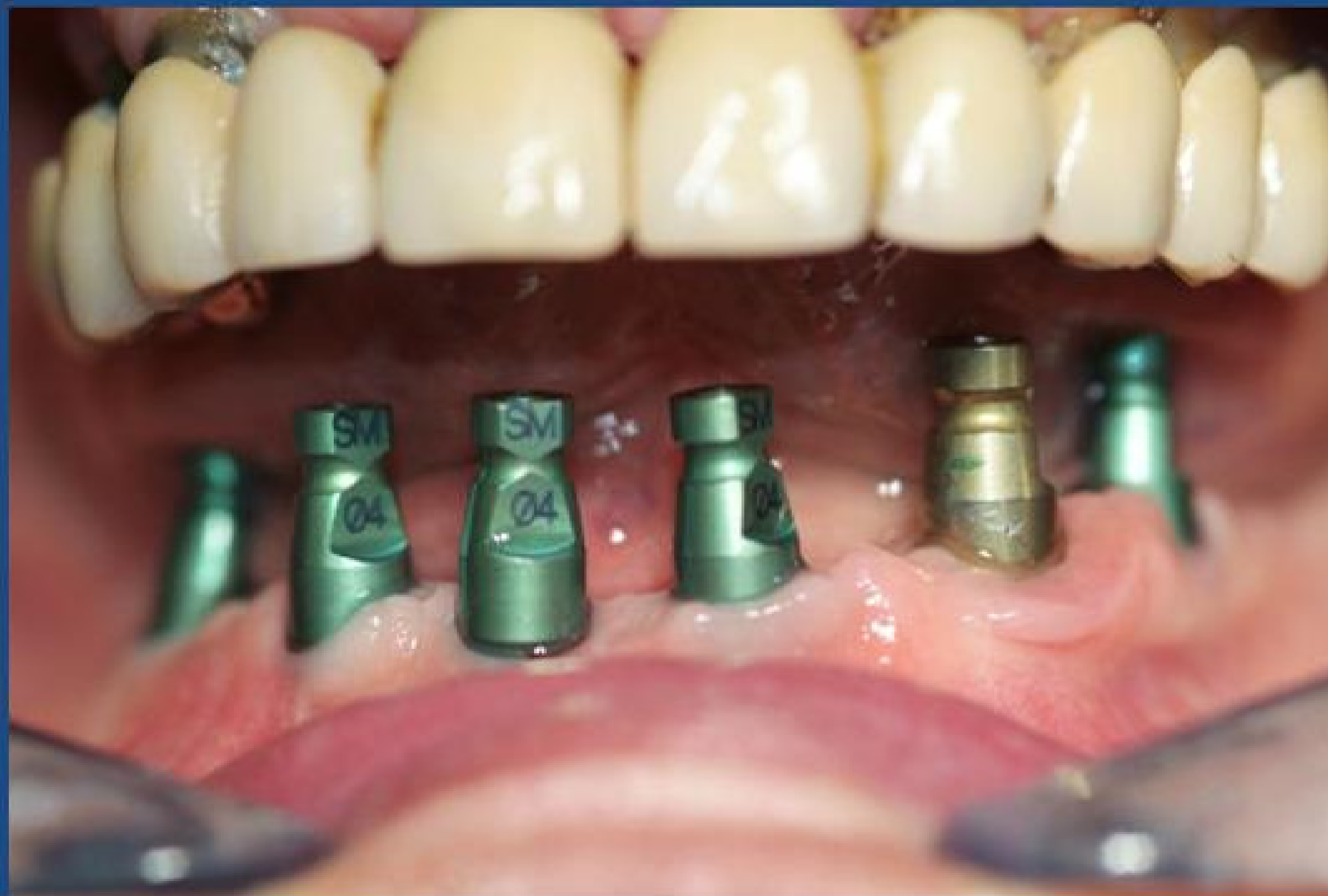Controllo radiografico dopo l'intervento

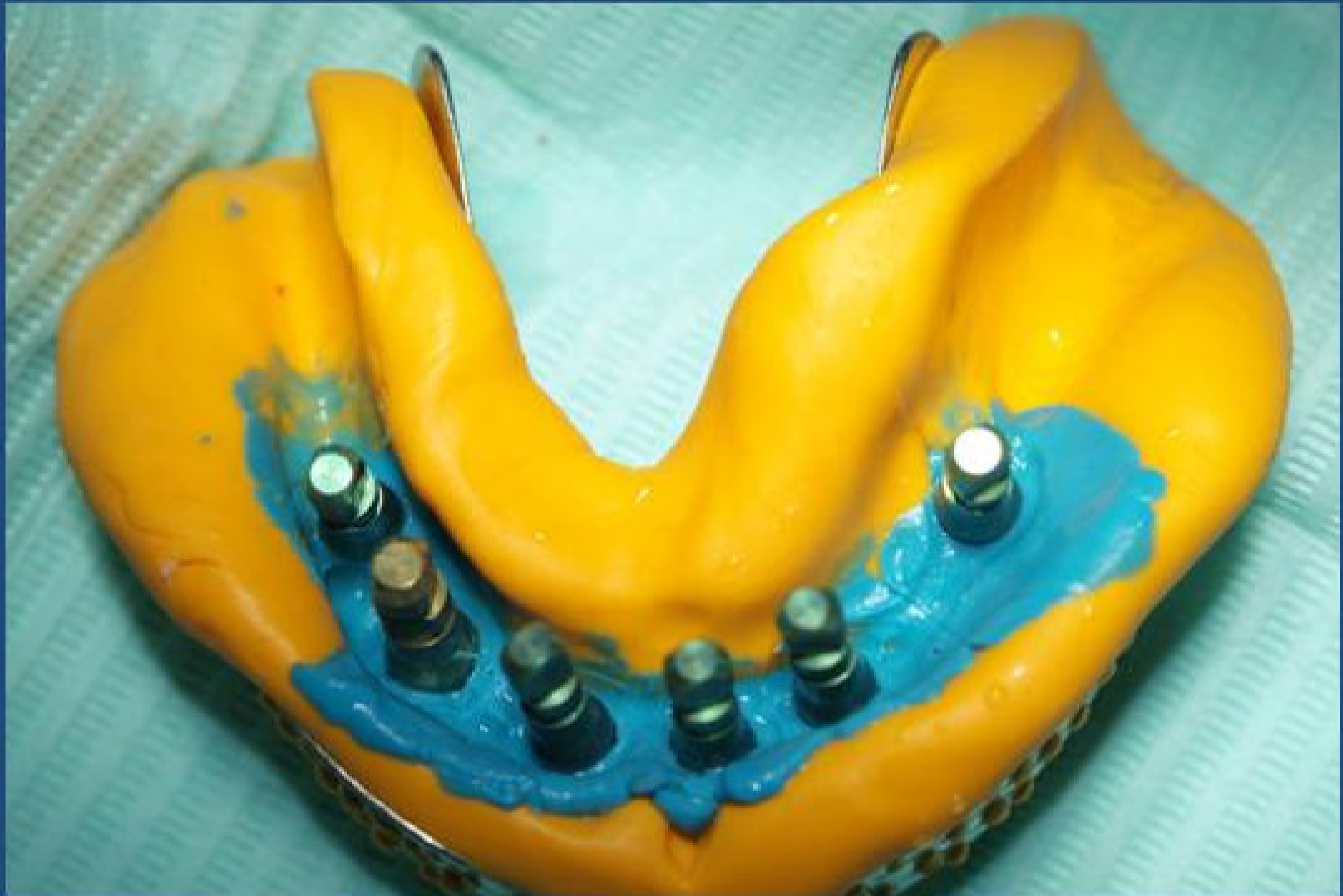

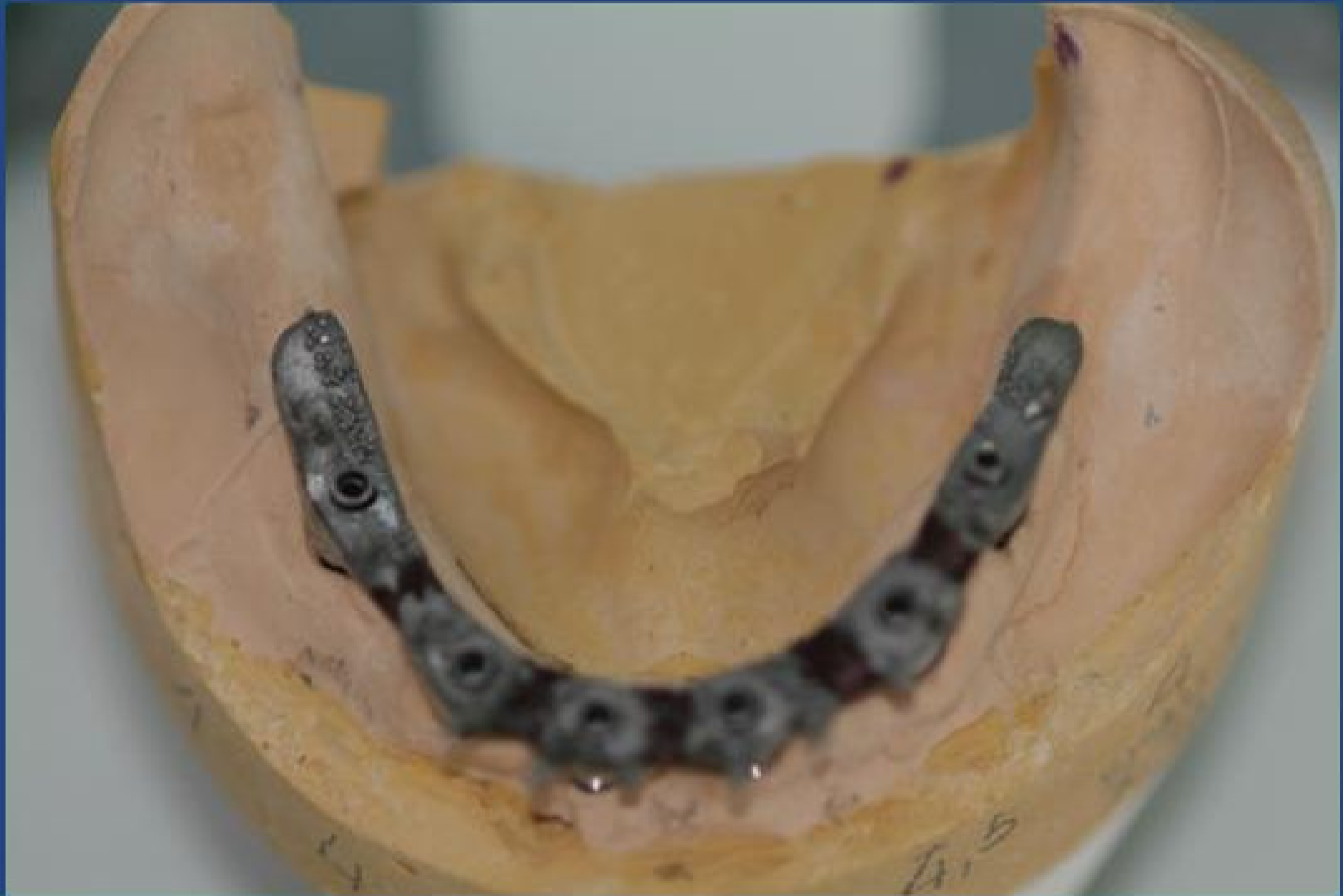Protesi provvisoria

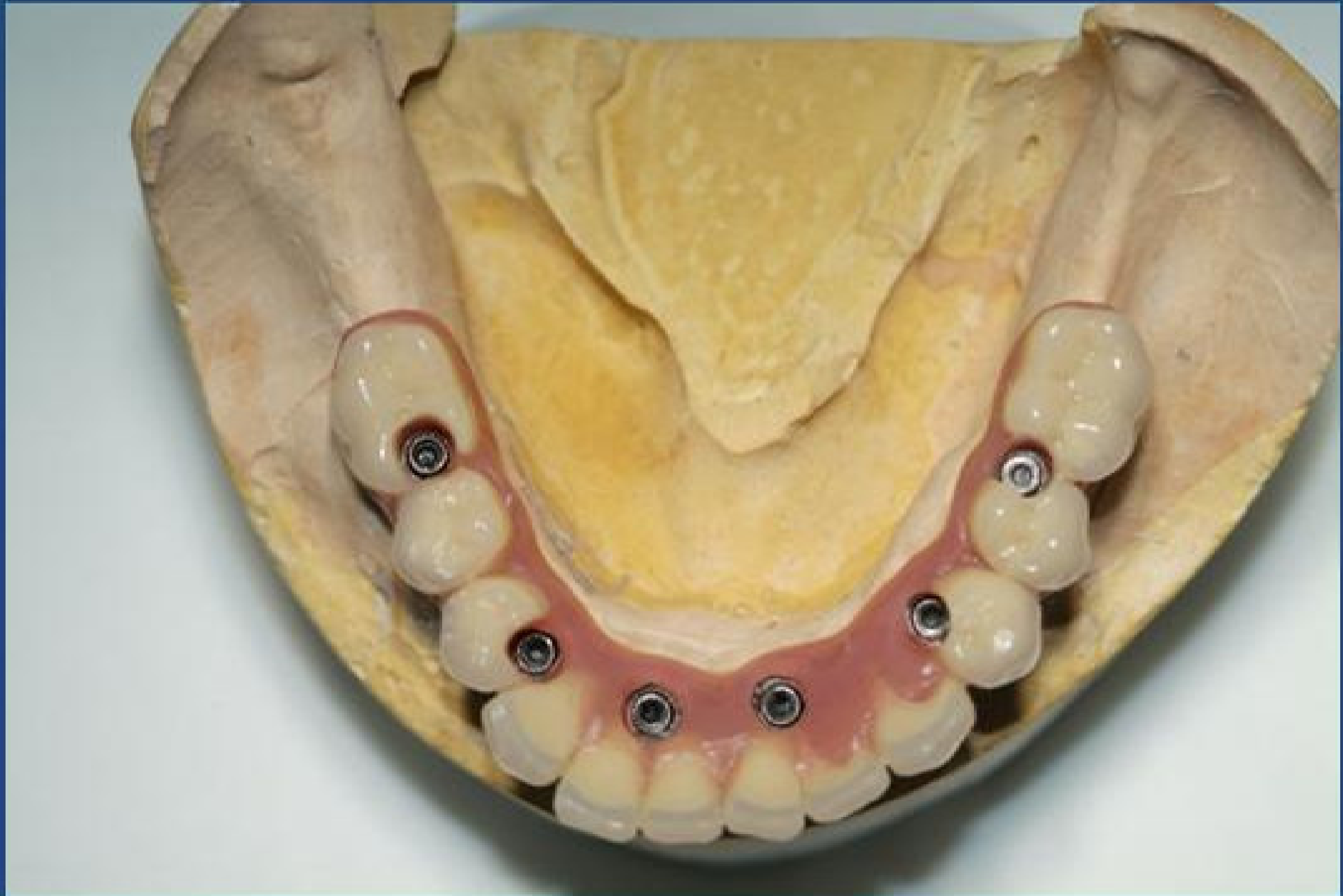


Impronte per definitivo dopo circa 4
mesi

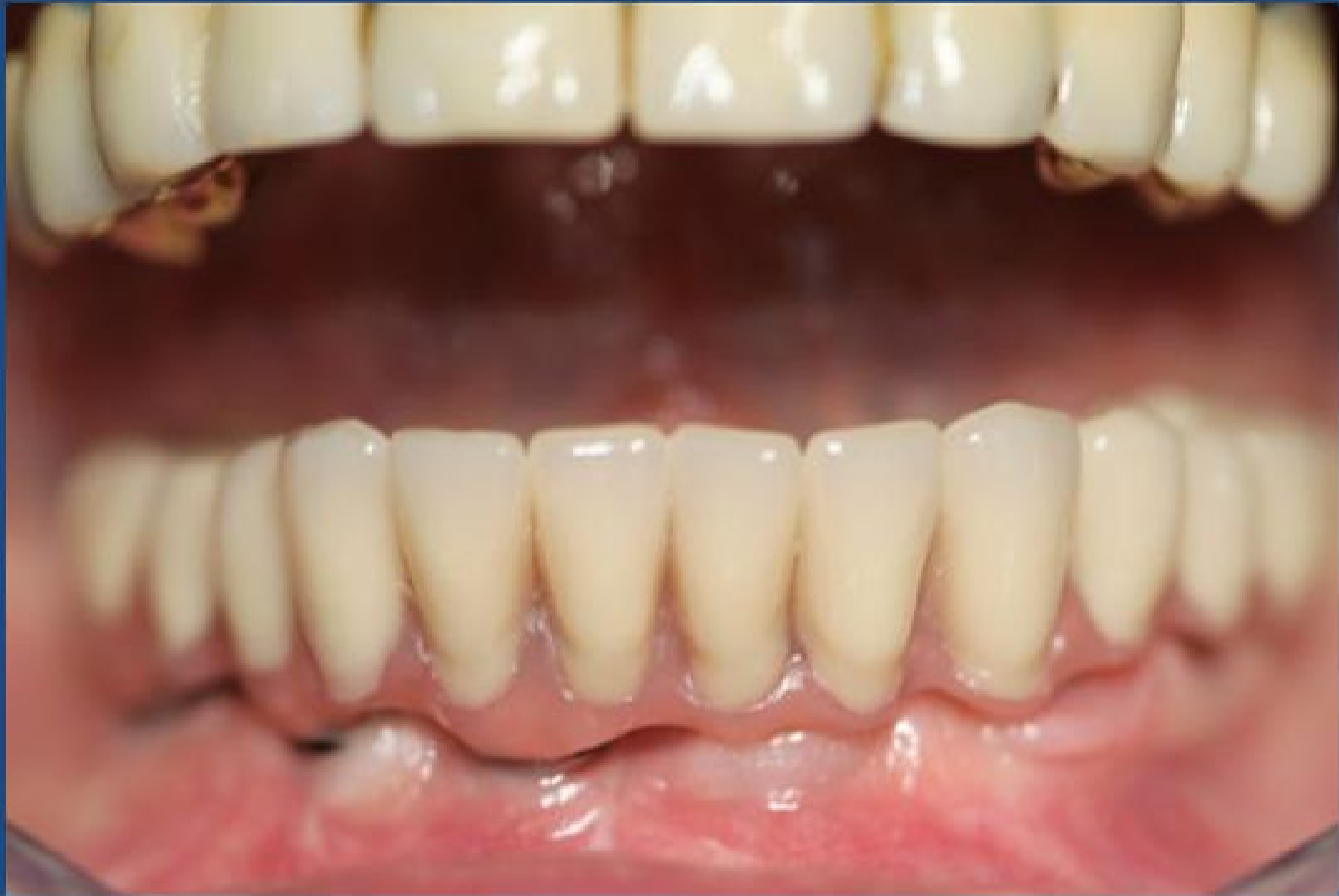


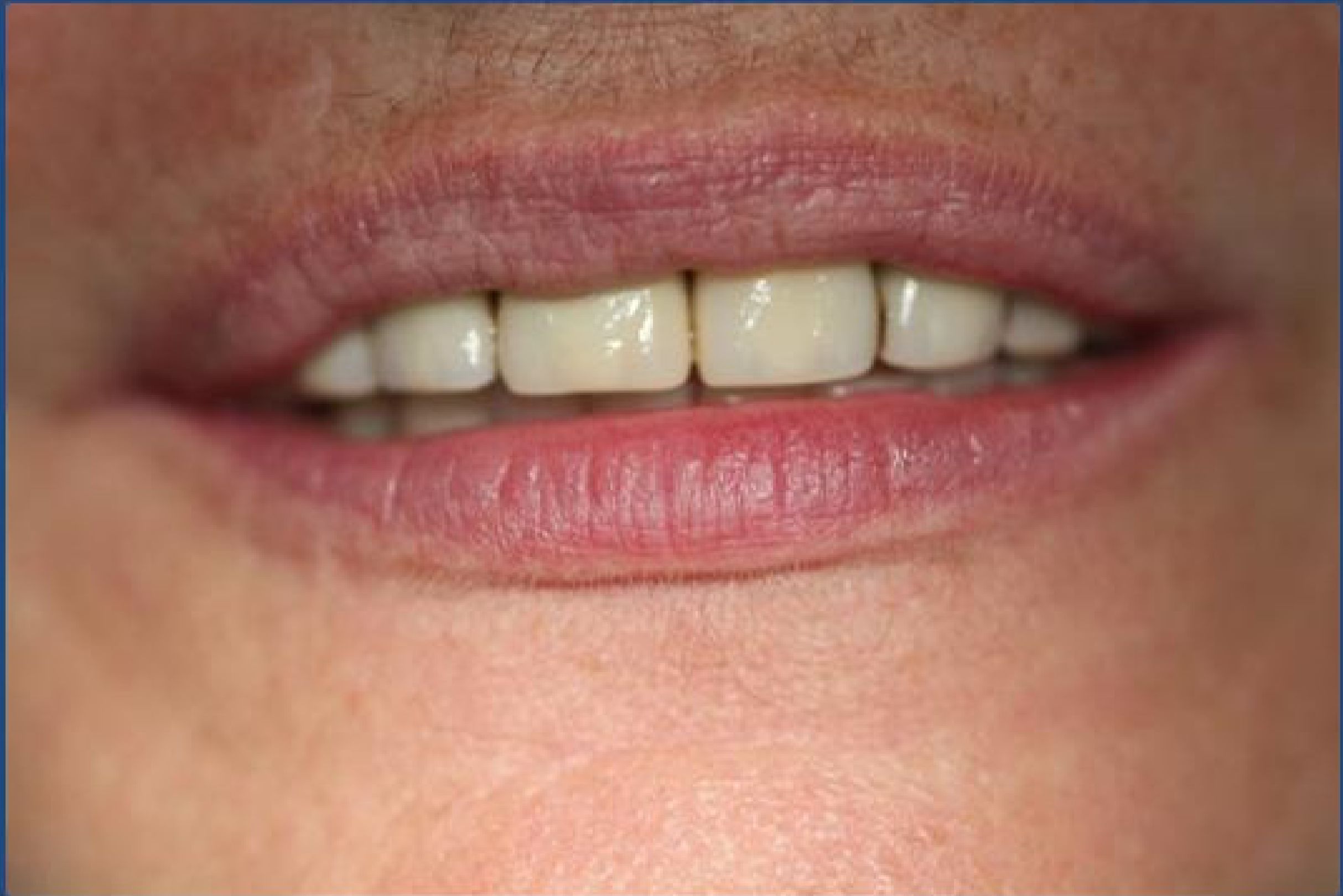




Protesi definitiva avvvitata





Controllo radiografico a fine terapie

